Revista Chilena de Neurocirugía 40: 2014

Intermuscular gluteal lipoma mimicking sciatic pain. Case report

Maurus Marques de Almeida Holanda[1], Gustavo de Moura Peixoto[2], Normando Guedes Pereira Neto[2], Rayan Haquim Pinheiro Santos[2], Artur Bastos Rocha[2], Stênio Abrantes Sarmento[1], Pedro Henrique Perez de Moura[2]

[1] Neurosurgeon, Associate Professor of Neurology at Federal University of Paraiba, João Pessoa, PB, Brazil.

[2] Medical Student at Federal University of Paraiba, João Pessoa, PB, Brazil.

Rev. Chil. Neurocirugía 40: 117-118, 2014

Abstract

Sciatic pain is a disabling pathology that can have various etiologies, but is rarely described as caused by an intermuscular gluteal lipoma. The authors describe a patient with a progressively worsening right sciatic pain for 6 months and with walking difficulty for 3 months. Magnetic resonance imaging (MRI) showed an expansive process compatible with lipoma between the gluteus maximus and medius, which was completely removed without sciatic nerve injury. After surgery, the patient is asymptomatic. This is an unusual case and represents an important differential diagnosis that should be considered in sciatic pain patients.

Key words: Sciatica, Lipoma, Lumbar Disc Herniation.

Resumen

El dolor ciático es una patología inhabilitante que puede tener diversas etiologías, pero rara vez se describe como causada por un lipoma glúteo intermuscular. Los autores describen a un paciente con un dolor ciática derecha que empeora progresivamente durante 6 meses y con dificultad para caminar durante 3 meses. La resonancia magnética (RM) mostró un proceso expansivo compatible con lipoma entre el gluteo máximo, y el glúteo medio. El lipoma fue retirado por completo y sin lesión del nervio ciático. Después de la cirugía, el paciente está asintomático. Este es un caso inusual y representa un importante diagnóstico diferencial que debe ser considerado en los pacientes con ciática.

Palabras clave: Ciática, Lipoma, Hernia Discal Lumbar.

Introduction

Lipoma is the most common benign tumor of soft tissues. It consists mainly of fatty tissue, usually subcutaneous, but when occurring in deeper tissues it may compress adjacent structures such as nerves[1]. Treatment is not usually required unless it is malignant, produces pain, restricts movement or is aesthetically compromising for the patient[2]. We report the case of a gluteal lipoma which mimicked symptoms of disc herniation due to compression of the sciatic nerve. This type of lipoma is uncommon and is described infrequently in the literature.

Case Report

Caucasian female, 63, presents with progressively worsening right sciatic pain for 6 months and with walking difficulty due to pain for about 3 months. The patient denies history of cancer and accidents involving buttocks or legs. She did not report constipation, tenesmus or incontinence.
On physical examination, Lasègue's sign was absent on both sides. Patient displayed intense pain on palpation of the left gluteal region, however without evidence of masses or palpable lesions.
Computed tomography (CT) scan of the spine showed discopathy on L4-L5, L5-S1. Magnetic resonance imaging (MRI), Figures 1 and 2, showed an expansive process compatible with lipoma in the gluteal region, between the gluteus maximus and medius. Electromyography (EMG) showed a change of conduction in the sciatic nerve in the gluteal topography. Figure 3 shows the lipomatous lesion, visualized after separation of the gluteus medius muscle. The lipoma was completely removed without sciatic

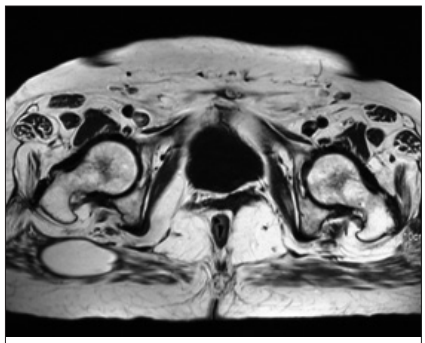

Figure 1. T1-weighted magnetic resonance image showing high signal of the lipomatous lesion.

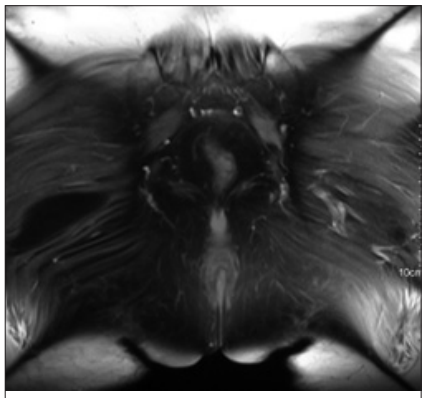

Figure 2. T2-weighted magnetic resonance image showing low signal of the lipomatous lesion.

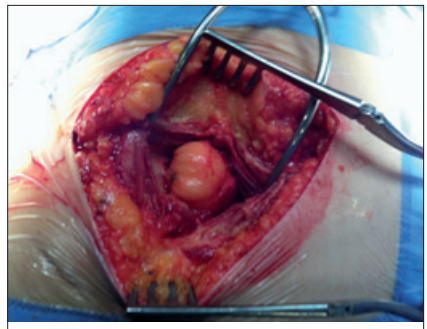

Figure 3. Perioperative visualization of a lipomatous lesion after separation of the gluteus medius muscle.

nerve injury. After surgery, the patient is asymptomatic.

Discussion

The sciatic nerve fibers are derived from the L4, L5, S1 and S2 roots of the sacral plexus and leave the pelvis through the greater sciatic foramen[3]. Sciatic nerve neuropathy may result from focal injury along the nerve pathway and can have various etiologies, such as compression, trauma, ischemia and neoplasia[4].

Lumbar sciatic pain presents itself clinically as low back pain radiating to the lateral part of the leg, following the path of the sciatic sensory innervations. The most common cause is nerve root compression when emerging between L3-L4, L4-L5 or L5-S1. The main causes of low back pain are: disc protrusions and herniations; spinal canal stenosis of lumbar spondylolisthesis; and piriformis syndrome[4]. Symptoms due to peripheral compression of the sciatic nerve are uncommon and, in general, raise suspicion of myelopathy or degenerative disease of the spine. However, in this case the low back pain resulted from compression of the sciatic nerve by a gluteal lipoma.

Lipomas are considered the most common tumors of soft tissues, consisting in mature adipocytes without atypia. When occurring more deeply, they can be intramuscular or intermuscular[2]. In our case, it was intermuscular, located between the gluteus maximus and gluteus medius.

Since morphological changes in the intervertebral discs are frequently present on MRI, the correlation between radiological and clinical findings must always be kept in mind. In our case, the patient had one lumbar degenerative discopathy; however it was not the cause of the symptoms.

A finding in the physical examination that aided in the diagnosis was intense pain along the sciatic nerve innervation while standing, possibly due to nerve compression by contraction of the gluteal muscles. However, when sitting or prone, the pain improved.

This case highlights not only the importance of the differential diagnosis of sciatic pain regarding extra-axial etiologies, but also the need for good correlation between clinical and radiological findings. For that purpose, the MRI should include the muscular structures and soft tissue adjacent to the sciatic nerve since they could be implicated in the genesis of symptoms.

Conclusion

This is an unusual case because the clinical symptoms of disk herniation were associated with an uncommon etiology. It represents a differential diagnosis that should be considered, especially since lipomas are a benign expansive process with distinct MRI features and with a favorable surgical outcome[5-7].

Disclosure: The authors report no conflict of interest concerning the materials or methods used in this study or the findings specified in this paper.

Recibido: 5 de junio de 2014
Aceptado: 1 de julio de 2014

References

1. Flores LP, Carneiro JZ: Peripheral nerve compression secondary to adjacent lipomas. Surg Neurol 2007; 67: 258-263.
2. Fernández EMLT et.al: Intermuscular lipoma of the gluteus muscles compressing the sciatic nerve: an inverted sciatic hernia. J Neurosurg 2012; 117: 795-799.
3. Yuen EC, So YT: Sciatic Neuropathy. Neurol Clin 1999; 17 :617-631.
4. Feinberg J, Sethi S: Sciatic Neuropathy: Case Report and Discussion of the Literature on Postoperative Sciatic Neuropathy and Sciatic Nerve Tumors. HSSJ 2006; 2: 181-187.
5. Hunt JA, Thompson JF: Giant infiltrating lipoma of the thigh causing sciatica. Aust N Z J Surg 1997; 67 :225-226.
6. Skipworth RJ, Smith GH, Stewart KJ, Anderson DN: The tip of the iceberg: a giant pelvic atypical lipoma presenting as a sciatic hernia. World J Surg Oncol 2006; 4: 33.
7. Botwin KP, Shah CP, Zak PJ: Sciatic neuropathy secondary to infiltrating intermuscular lipoma of the thigh. Am J Phys Med Rehabil 2001: 80: 754-758.

Correspondencia a:
Maurus Marques de Almeida Holanda.
E-mail address: maurusholanda@hotmail.com; Telephone number: +55-83-3222-7167